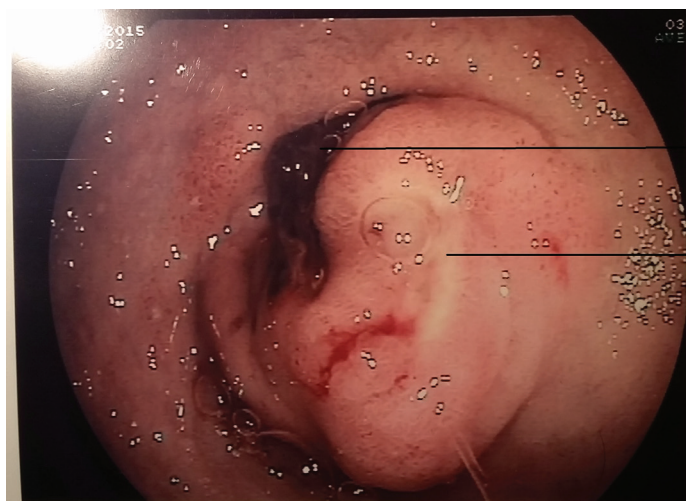


# Iconographie

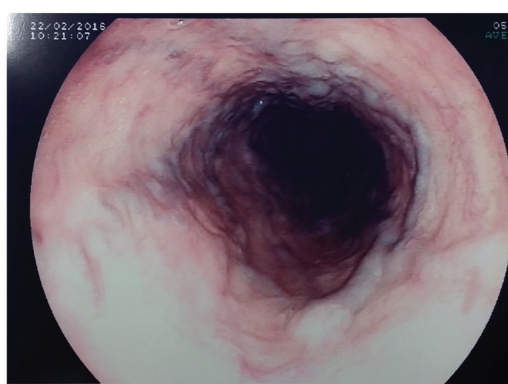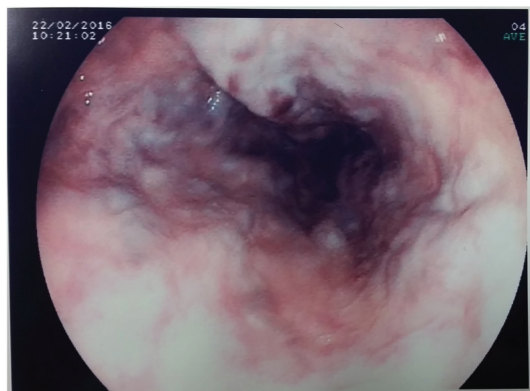

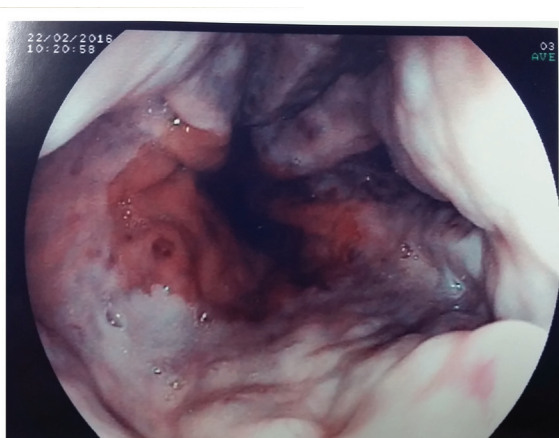
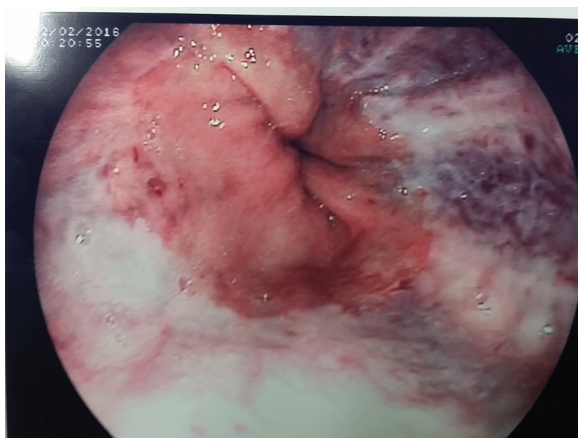Caillot de sang

Erosion de la muqueuse = ulcère

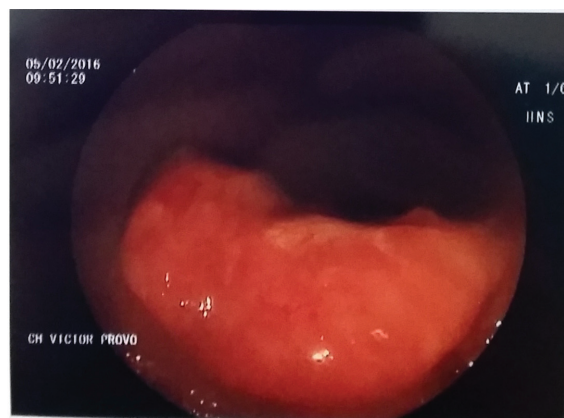
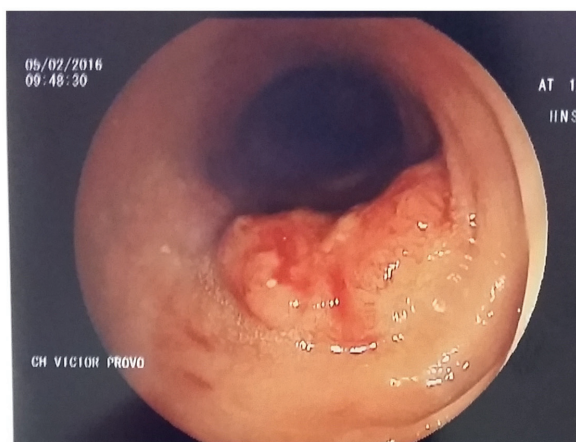
Pierre Mayer (décembre 2015)

Dossier 26 – Question 6



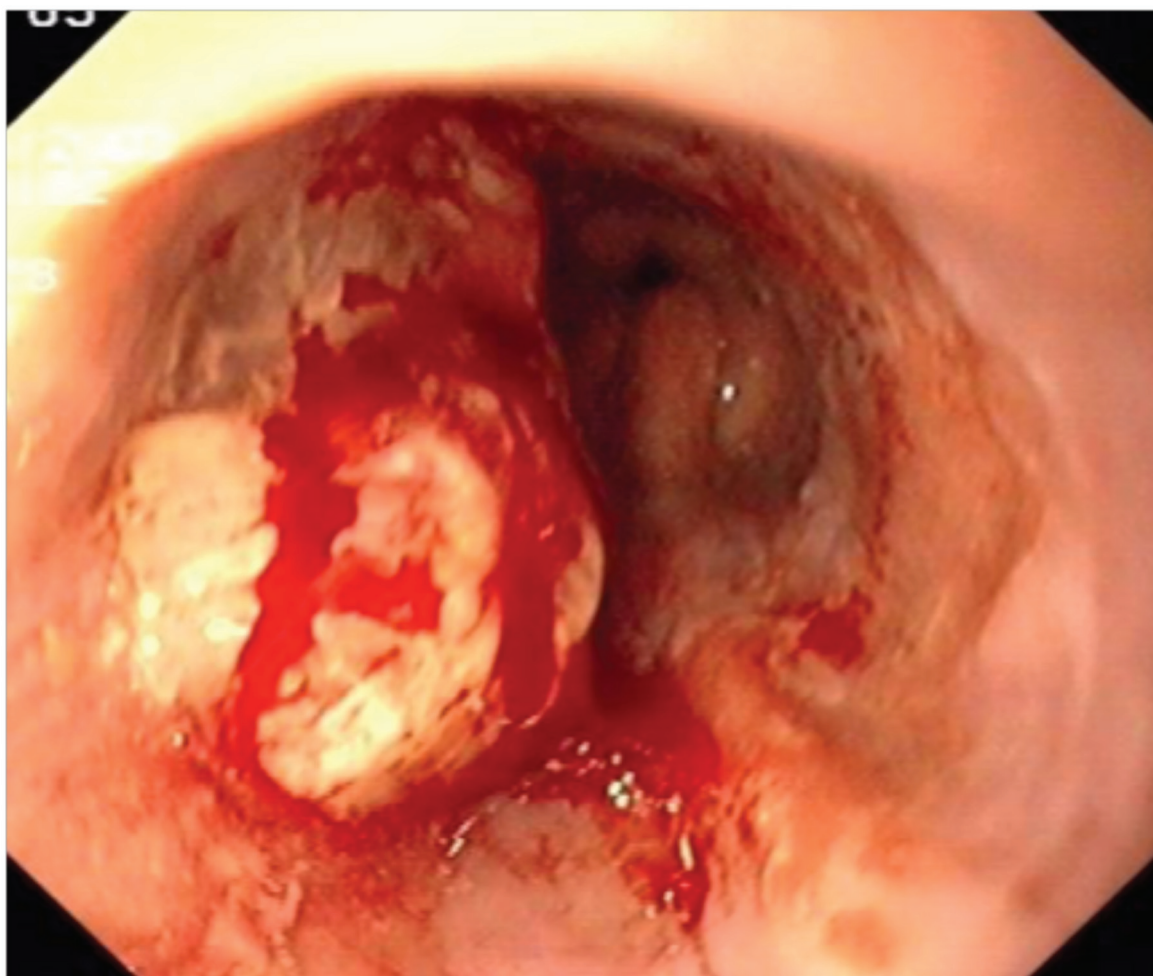
Fibroscopie oesogastroduodénale  
Pierre Mayer (février 2016)

Dossier 13 – Question 12



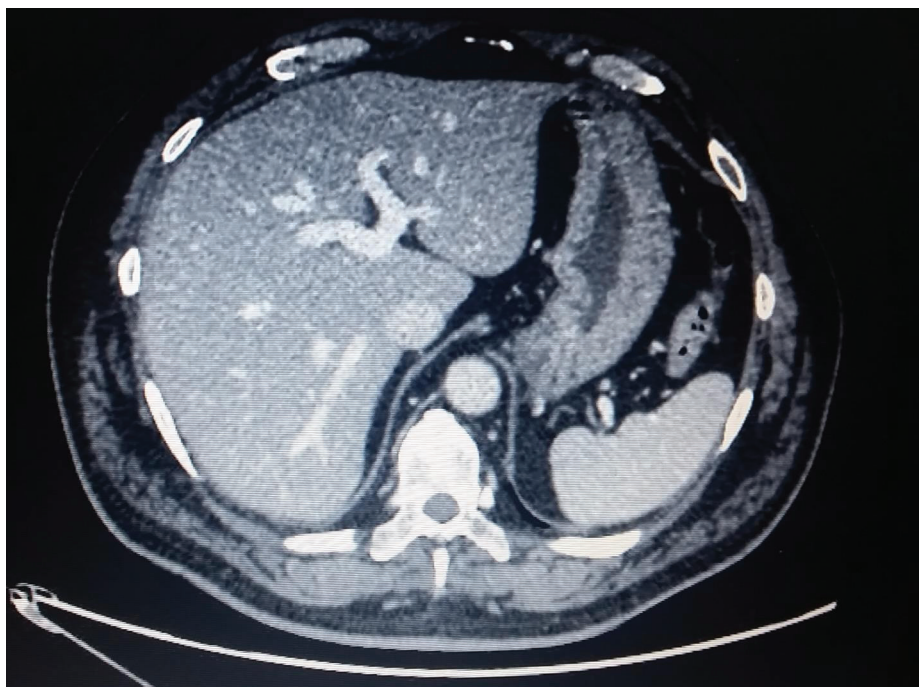
Pierre Mayer (février 2015)

Dossier 35 – Question 6

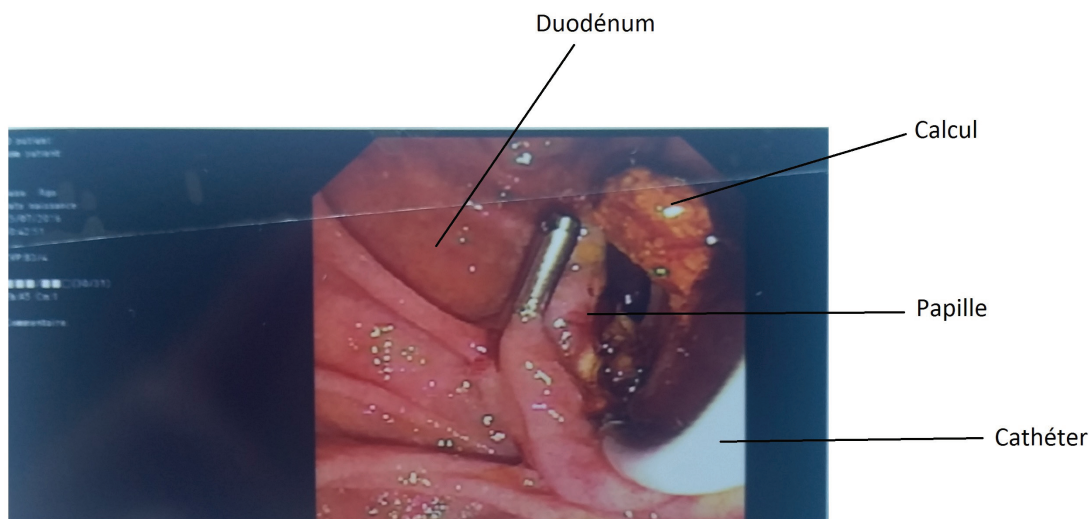


Dossier 2 – Question 14





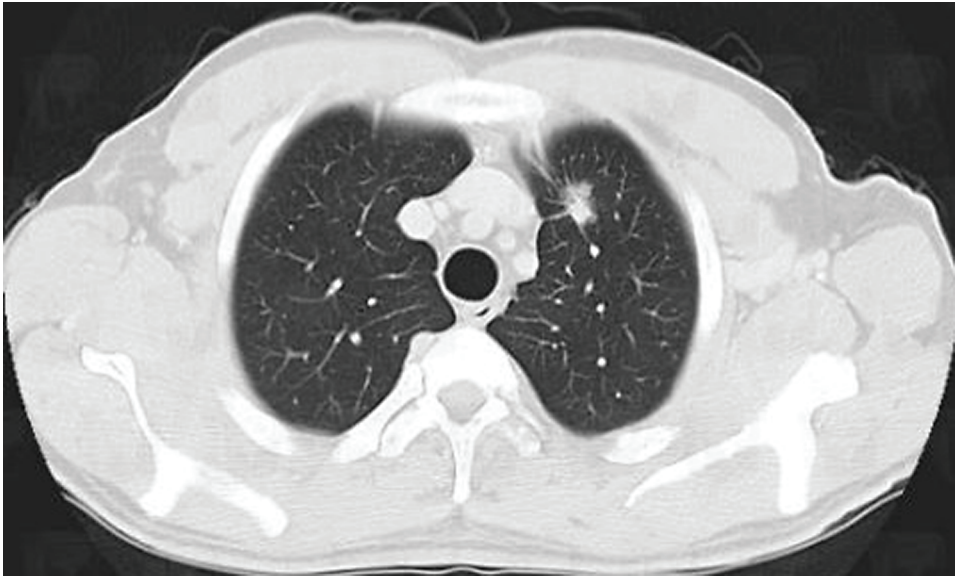
Dossier 24 – Question 6



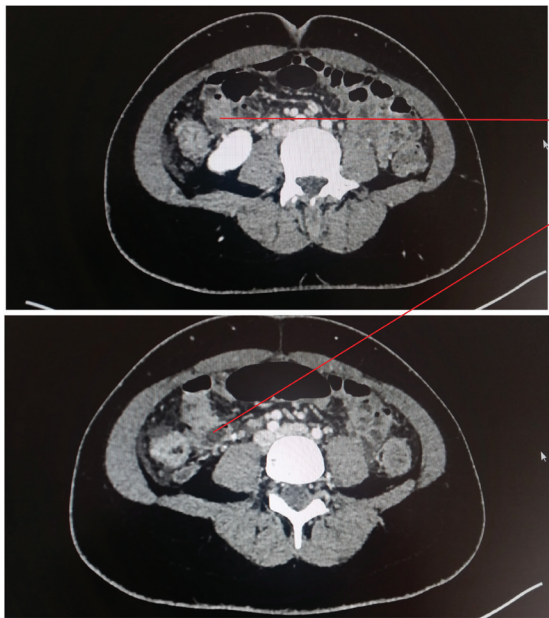
Pierre Mayer (Juin 2016)

Dossier 11 – Question 7



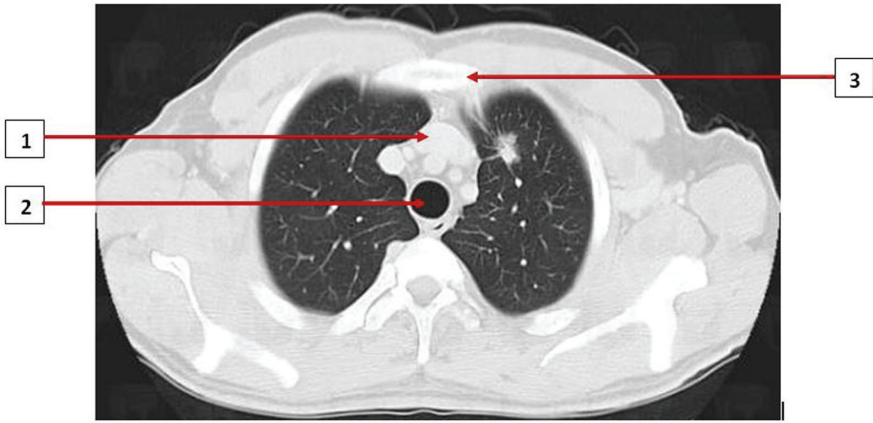


Dossier 28 – Question 6

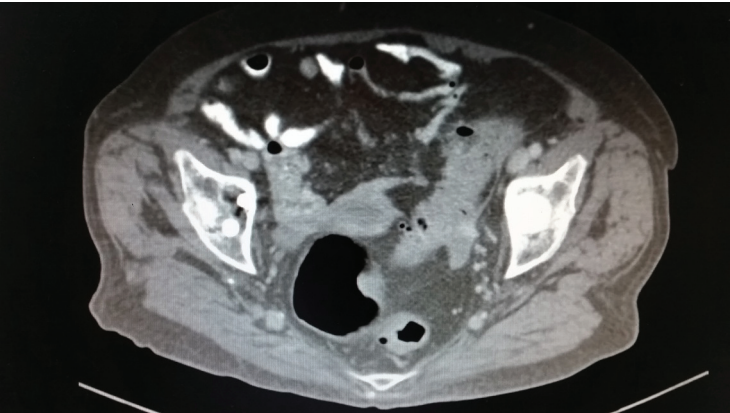


Iléite terminale sur scanner abdomino-pelvien  
avec injection de produit de contraste iodé  
  
Pierre Mayer (avril 2016)

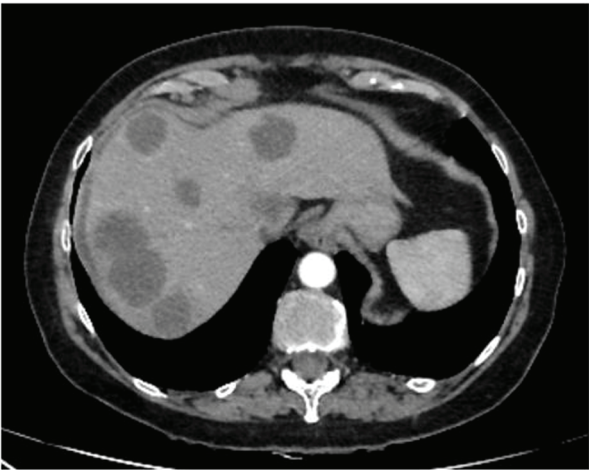Dossier 22 – Question 5



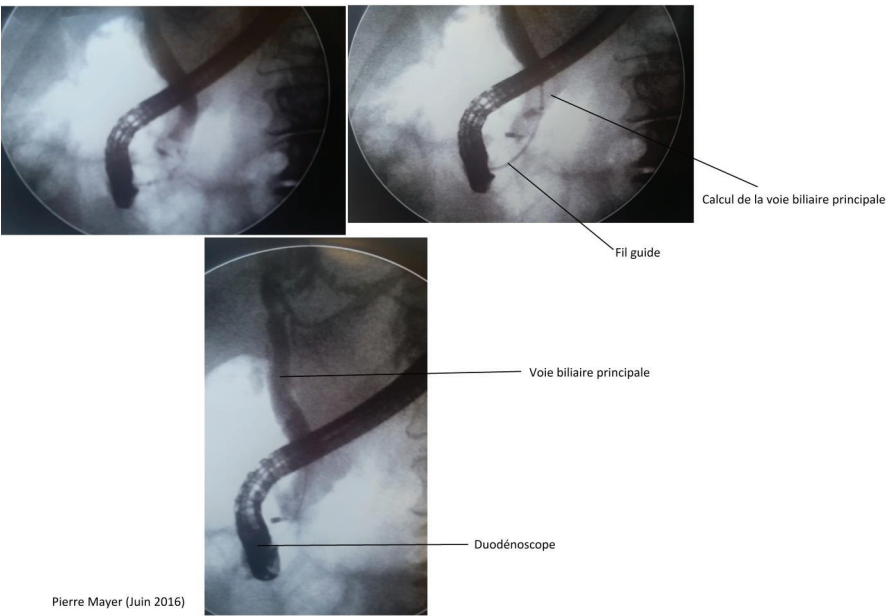
Dossier 28 – Question 7



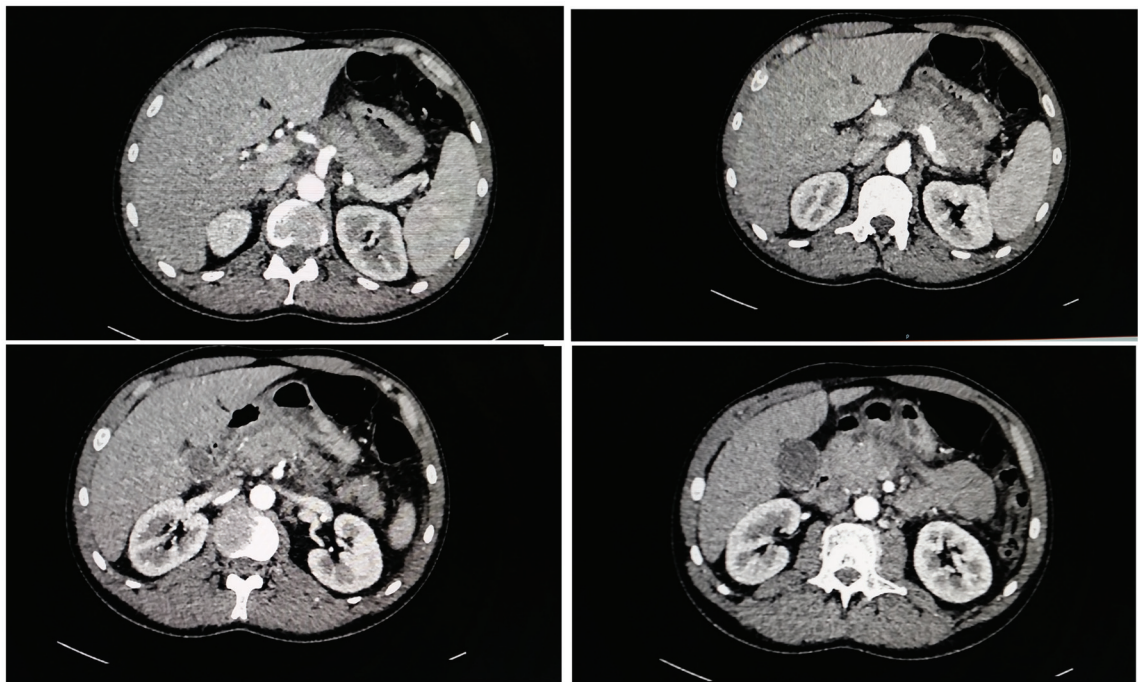
Dossier 14 – Question 10



Dossier 30 – Question 15

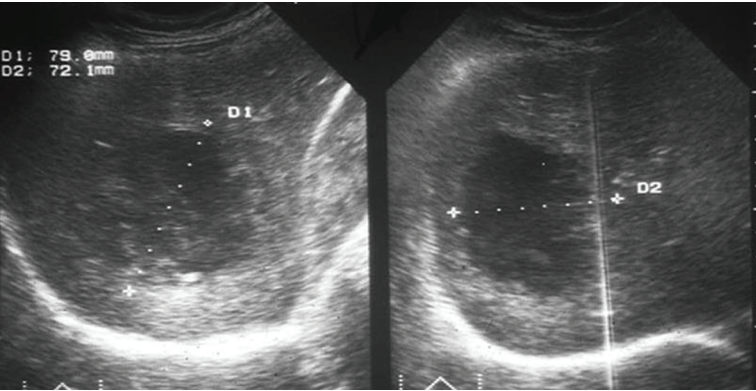


Dossier 11 – Question 7

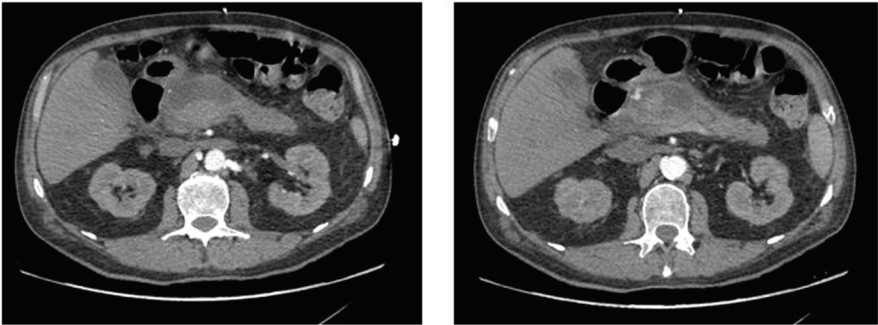


Dossier 5 – Question 5

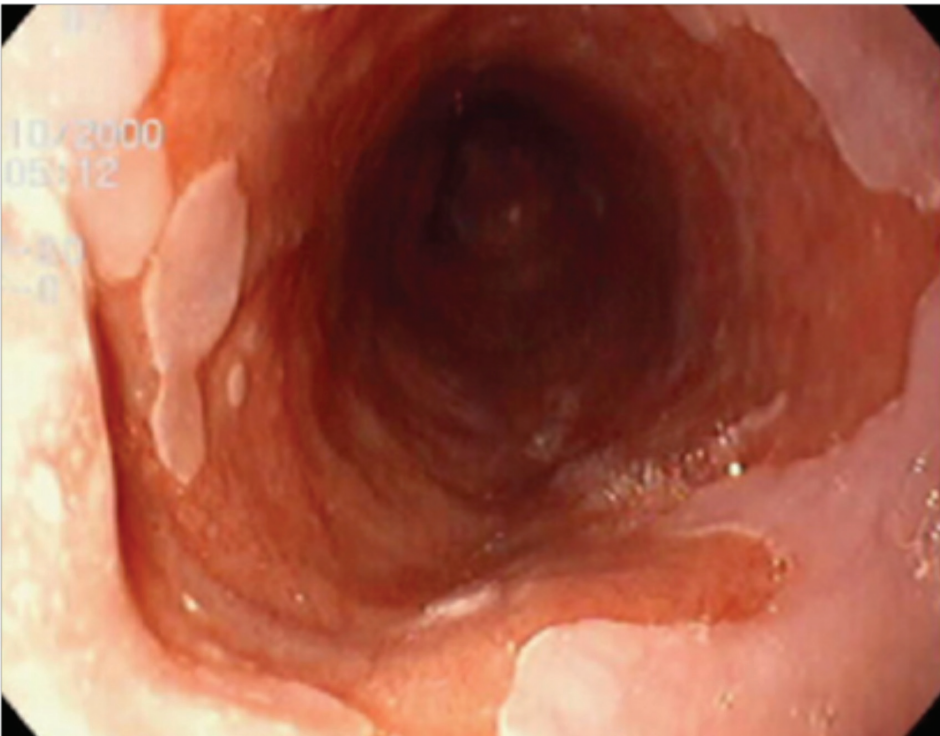




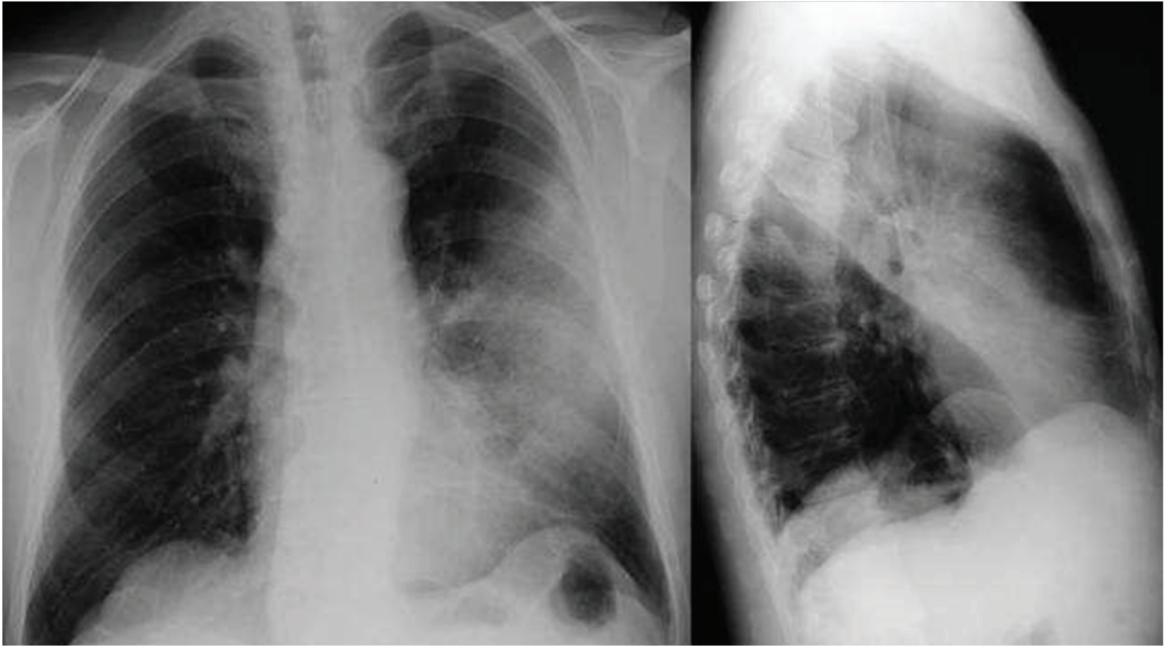
Dossier 9 – Question 6



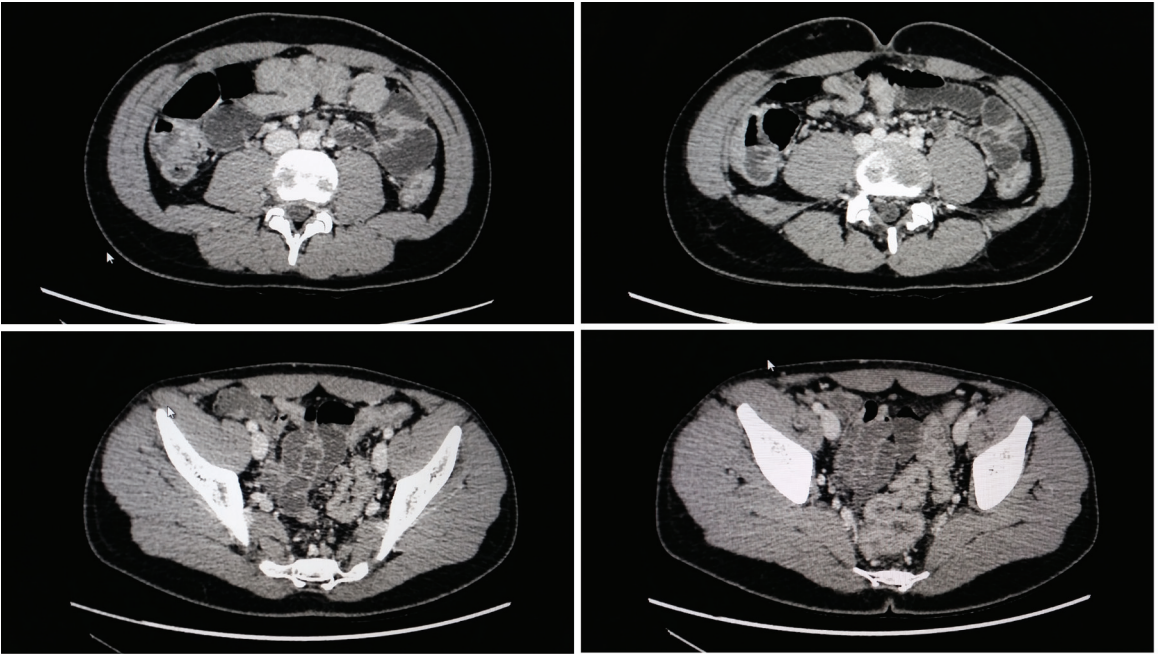
Dossier 15 – Question 9



Dossier 2 – Question 13



Dossier 31 – Question 13

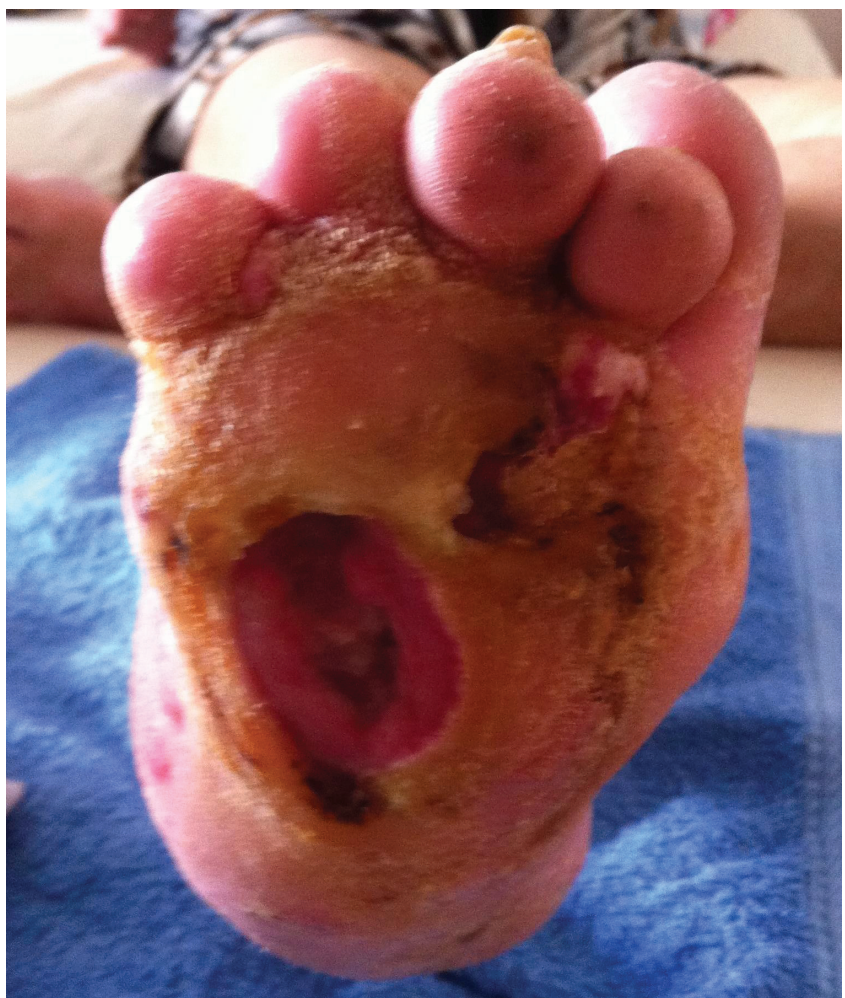

Scanner abdomino-pelvien au temps portal

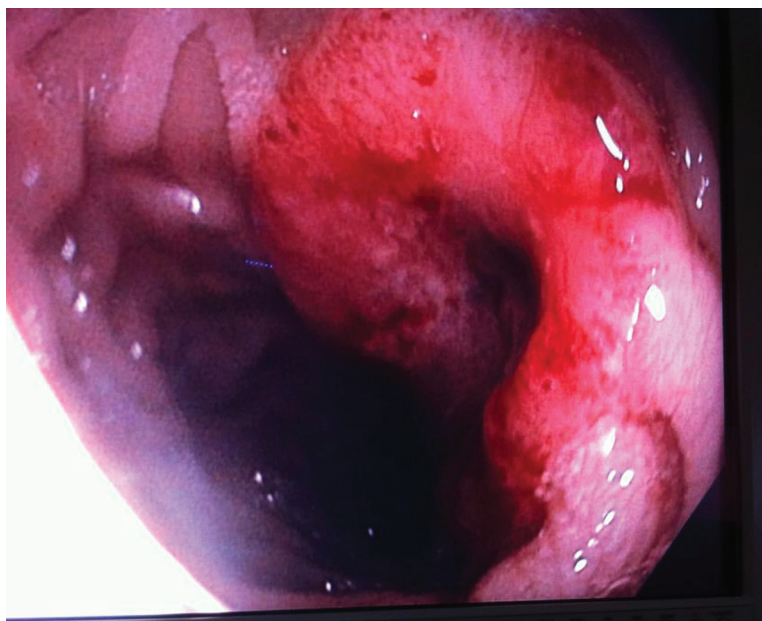Pierre Mayer (janvier 2016)

Dossier 18 – Question 4



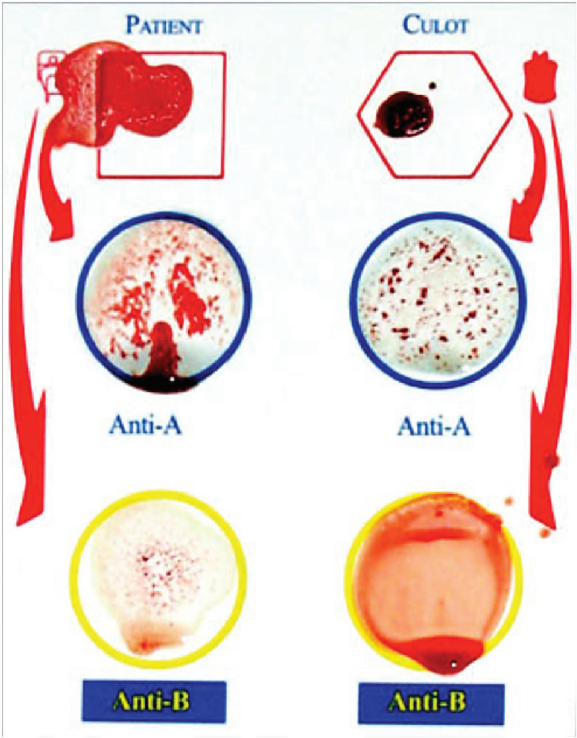


Dossier 8 – Question 12

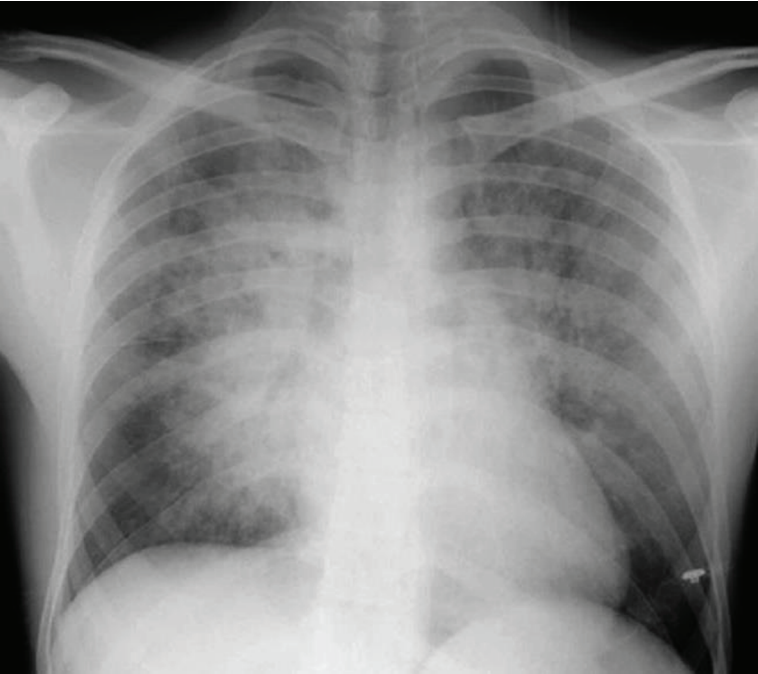


Dossier 4 – Question 10

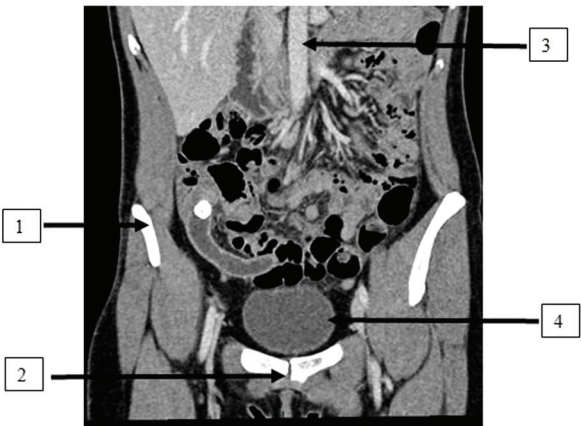




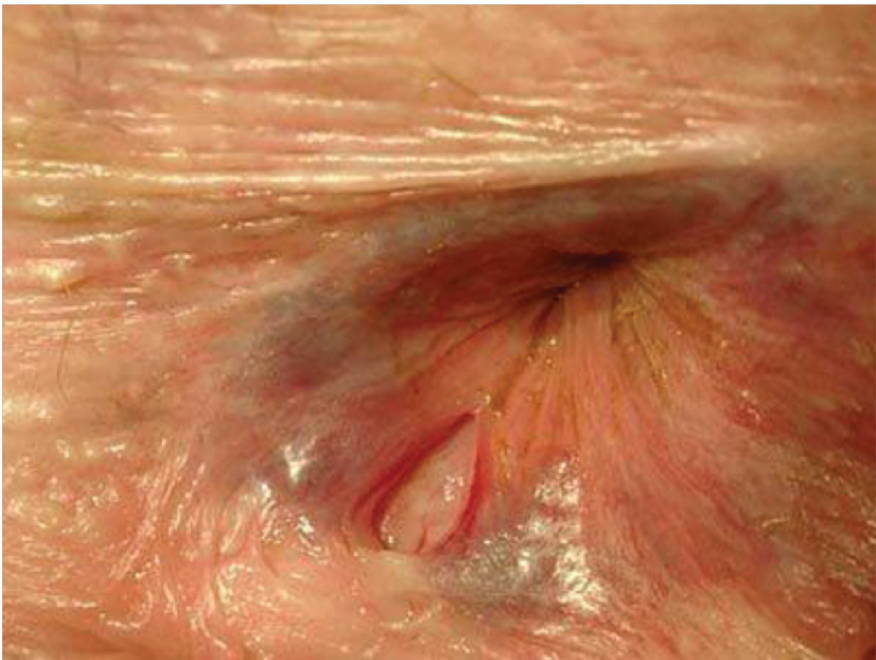
Dossier 16 – Question 10



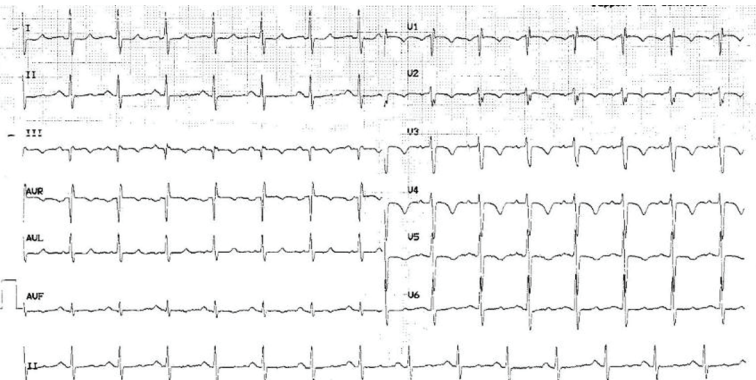
Dossier 32 – Question 6



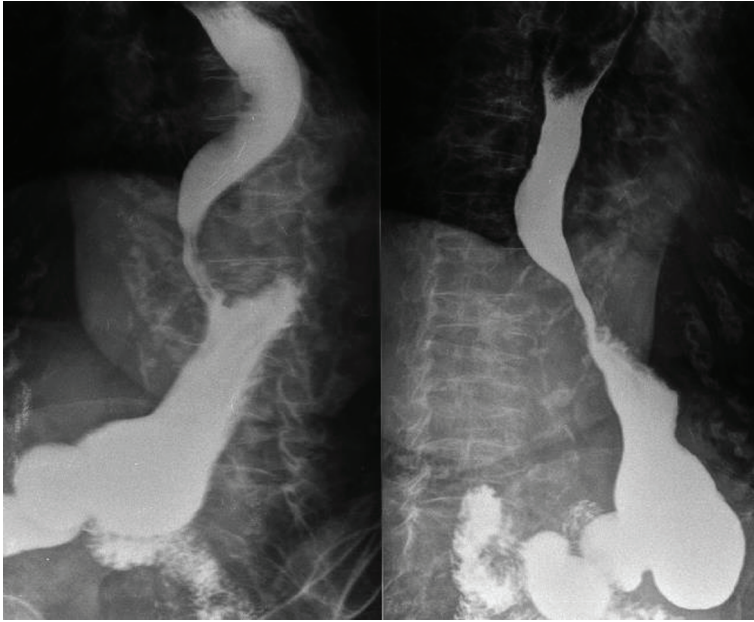
Dossier 7–Question 2



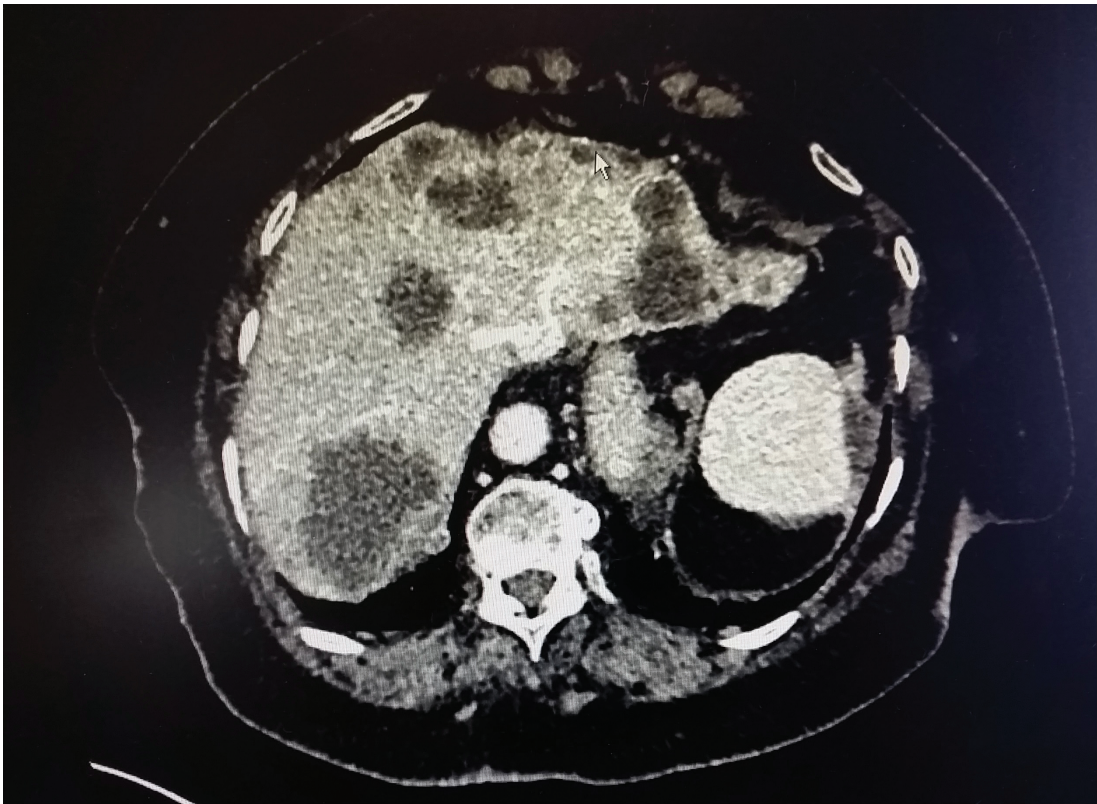
Dossier 3–Question 5



Dossier 36–Question 7



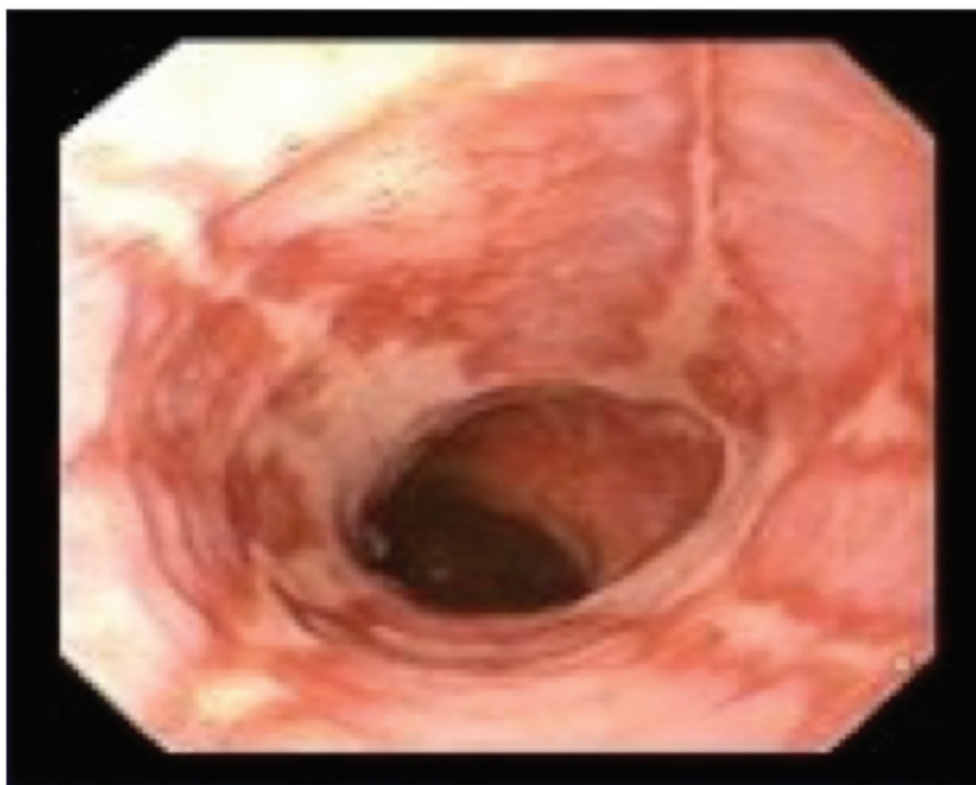Dossier 10 – Question 9



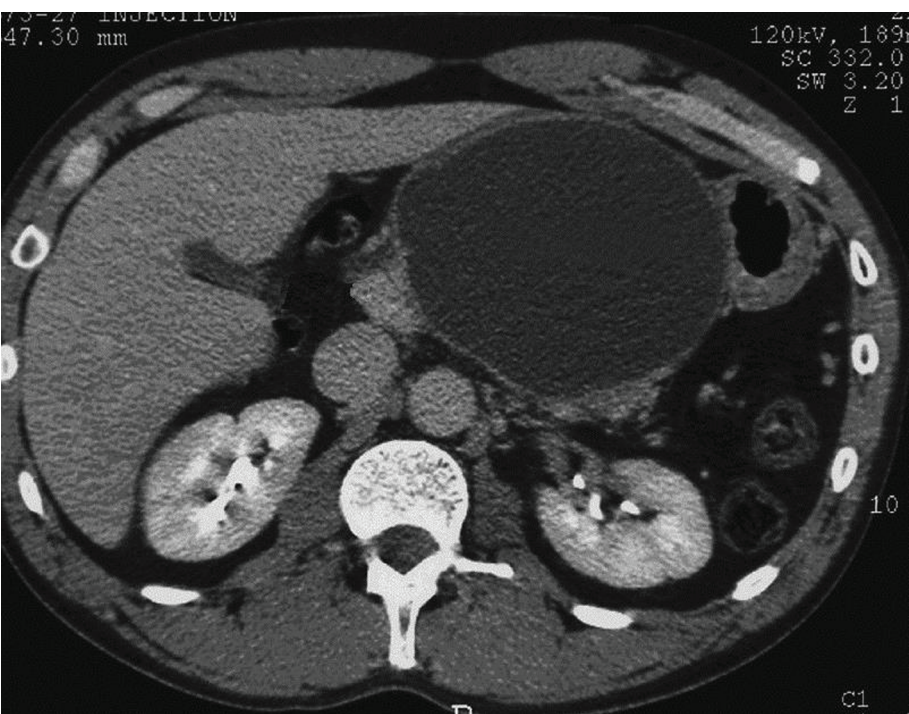
Scanner abdomino-pelvien avec injection de produit de contraste  
Pierre Mayer (décembre 2015)

Dossier 35 – Question 14

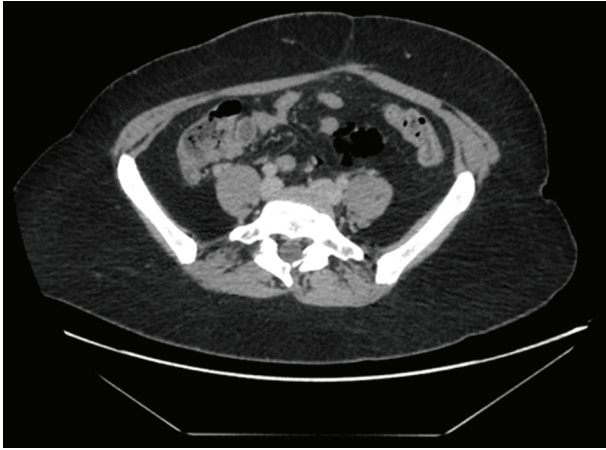




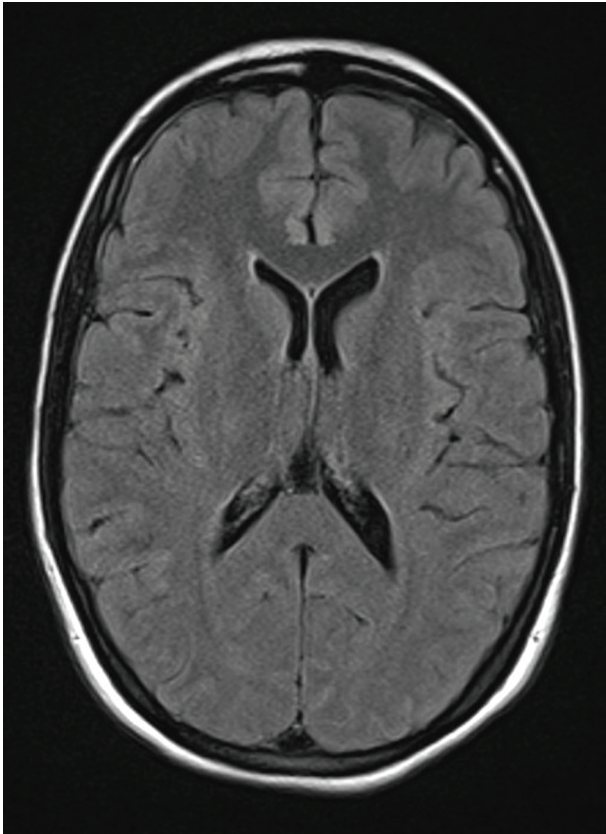
Dossier 2 – Question 9



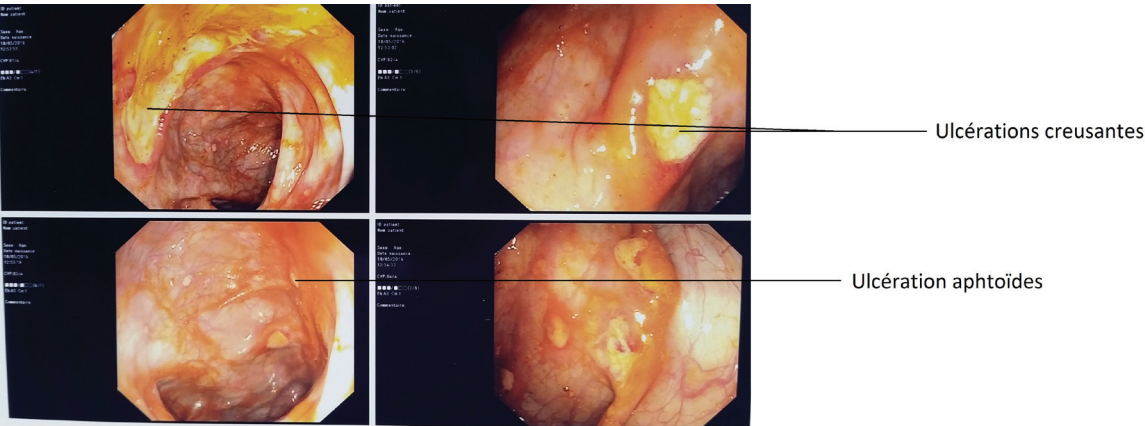
Dossier 23 – Question 9



Dossier1 – Question 2

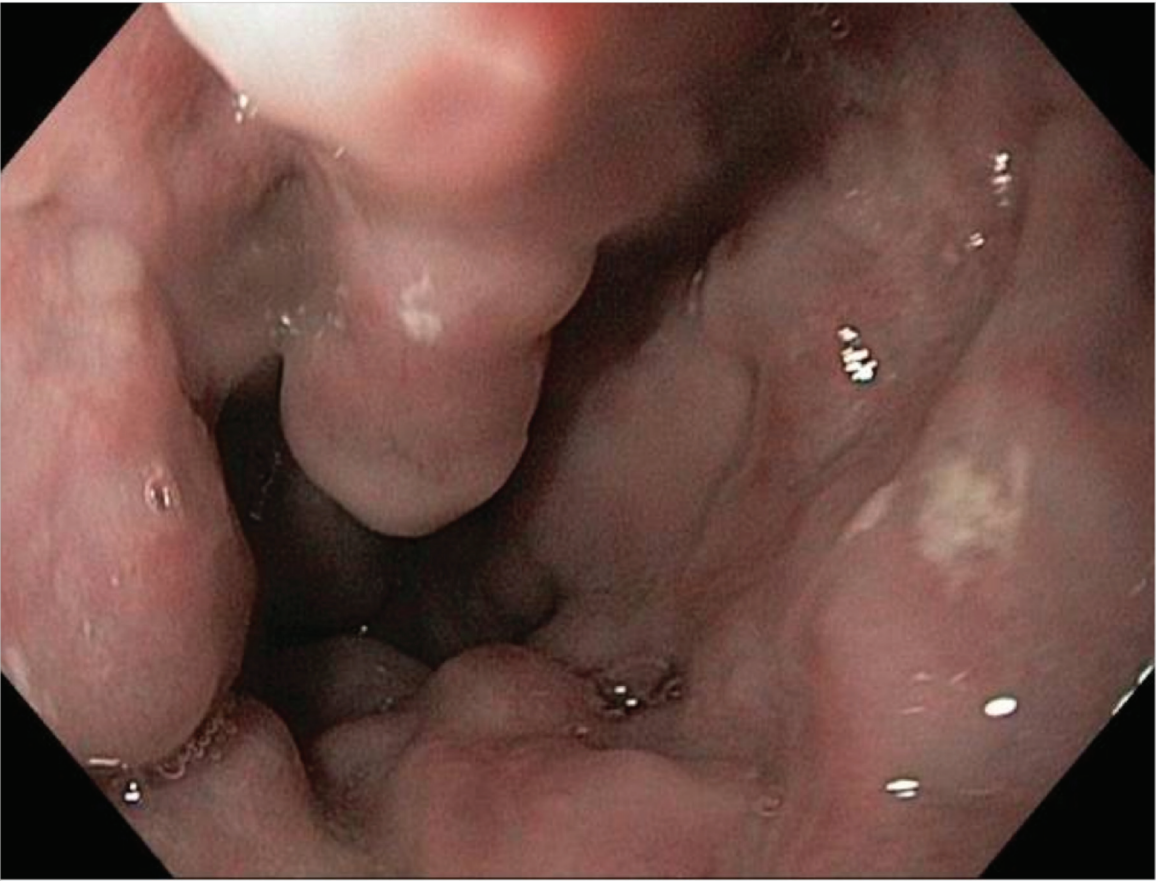


Dossier 20 – Question 5



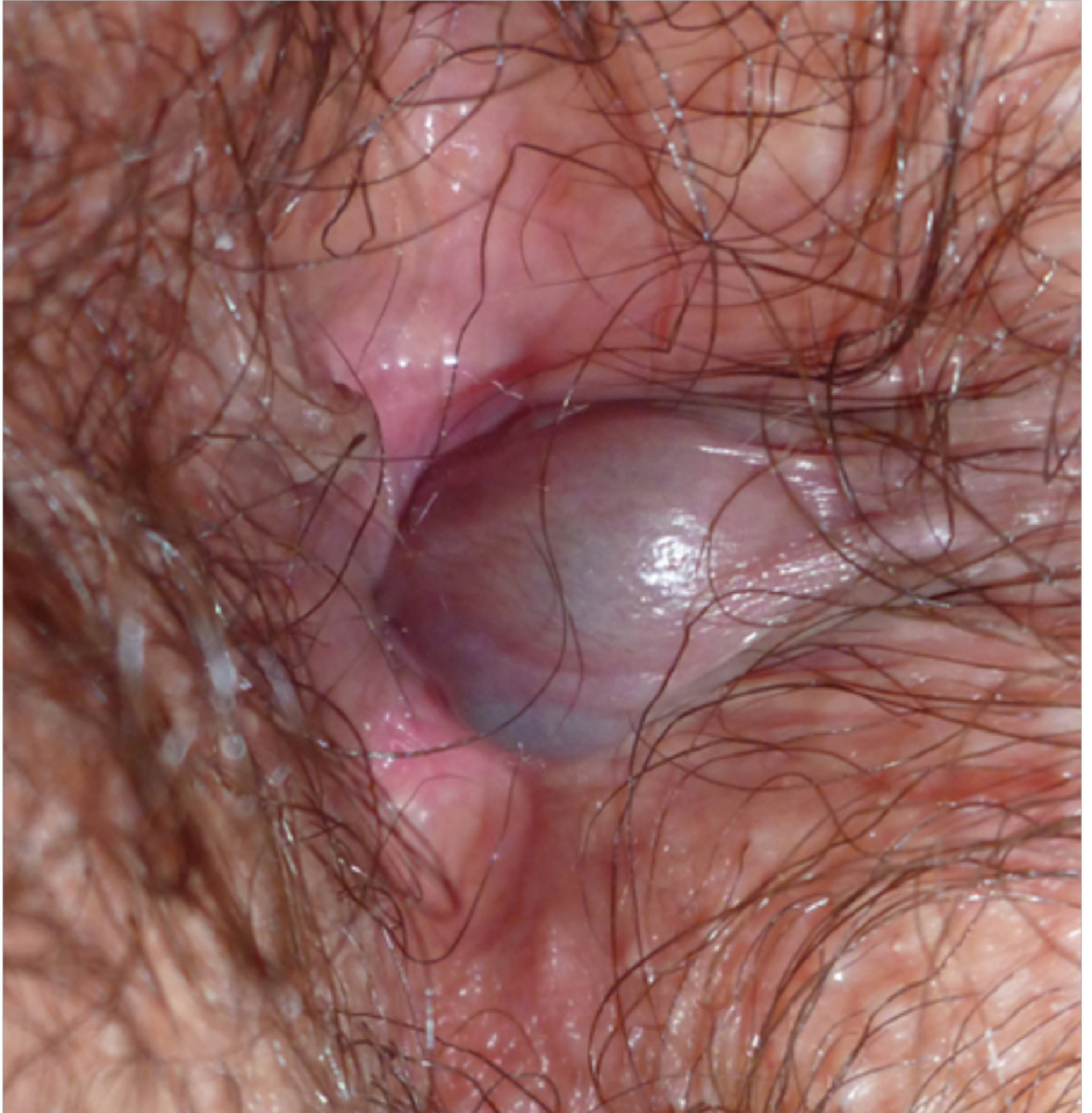Pierre Mayer (mai 2016)

Dossier 21 – Question 12

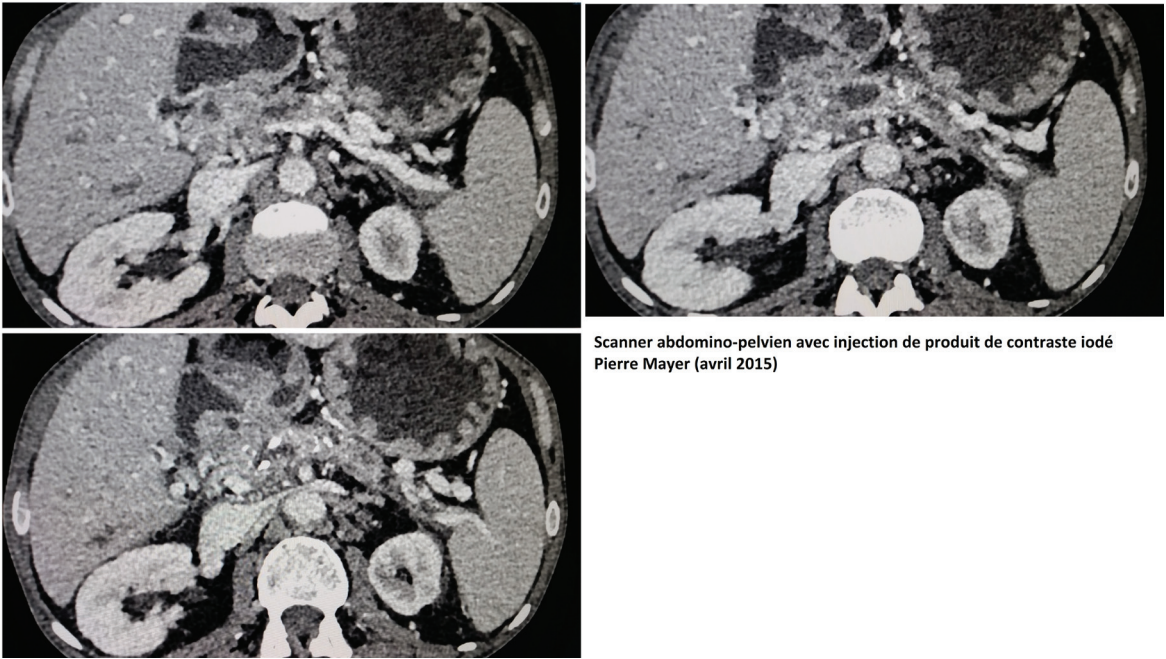


Dossier 16 – Question 12



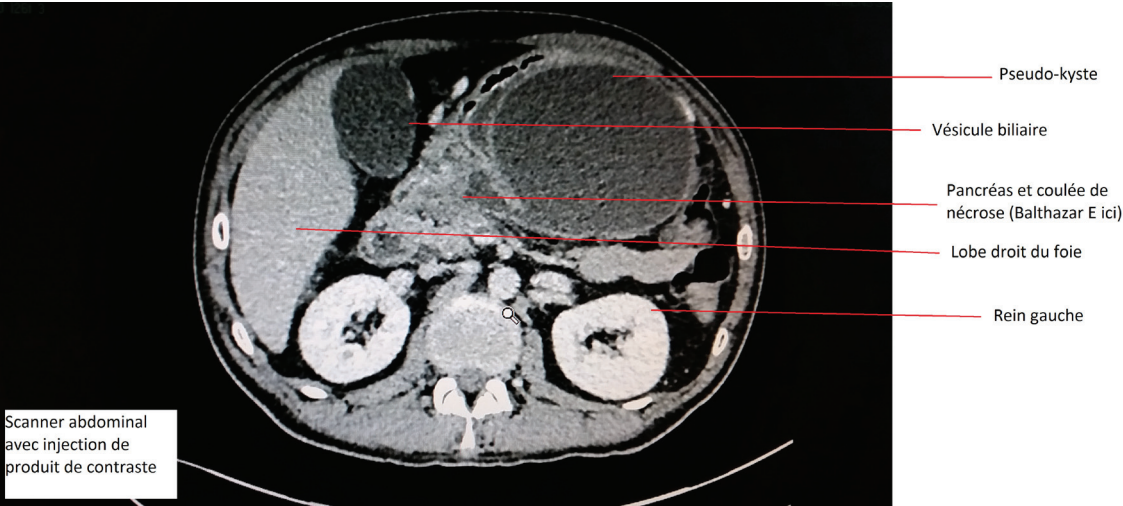


Dossier 3 – Question 9



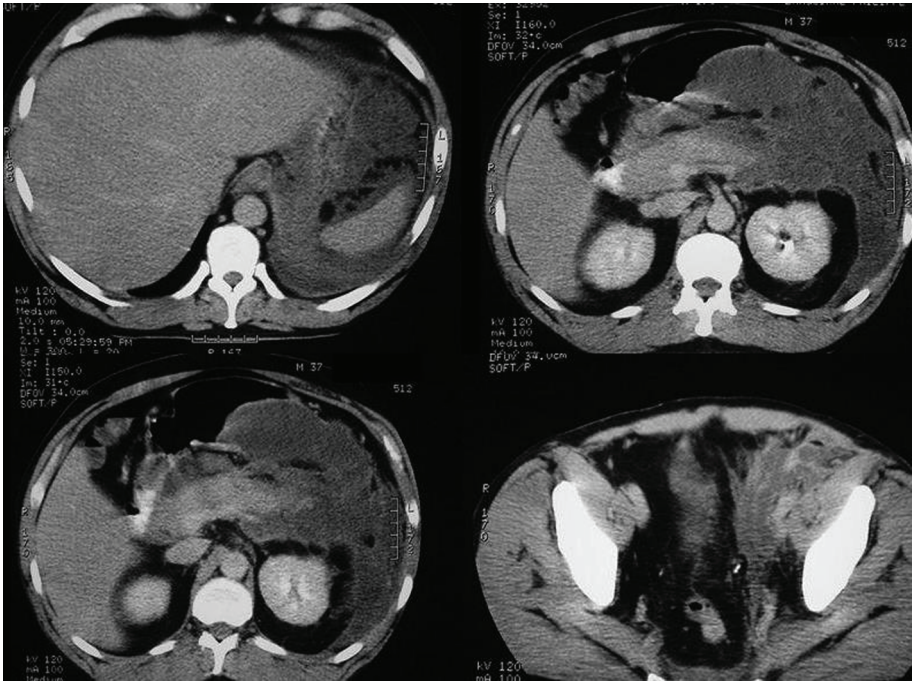Scanner abdomino-pelvien avec injection de produit de contraste iodé  
Pierre Mayer (avril 2015)

Dossier 5 – Question 7

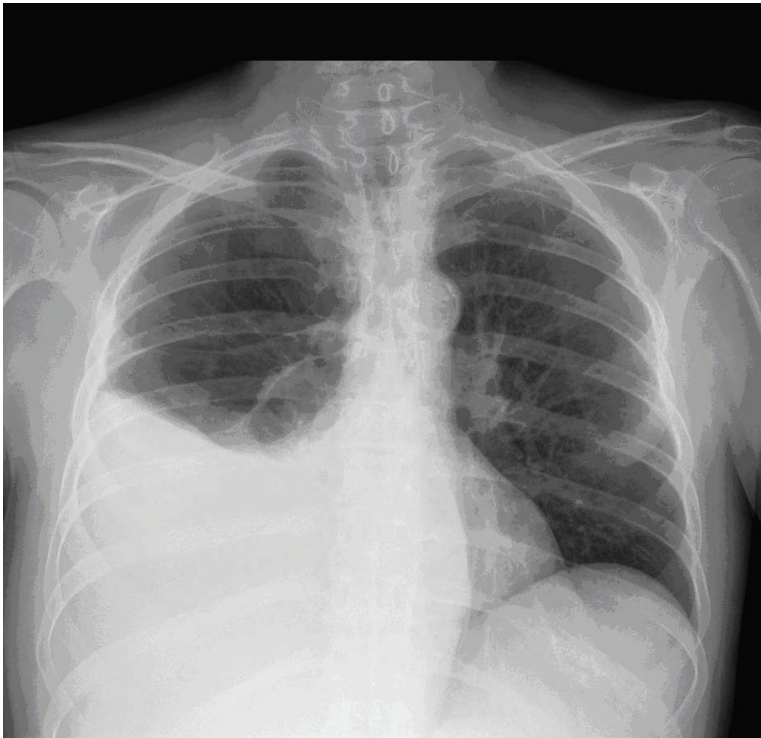


Dossier 11 – Question 11



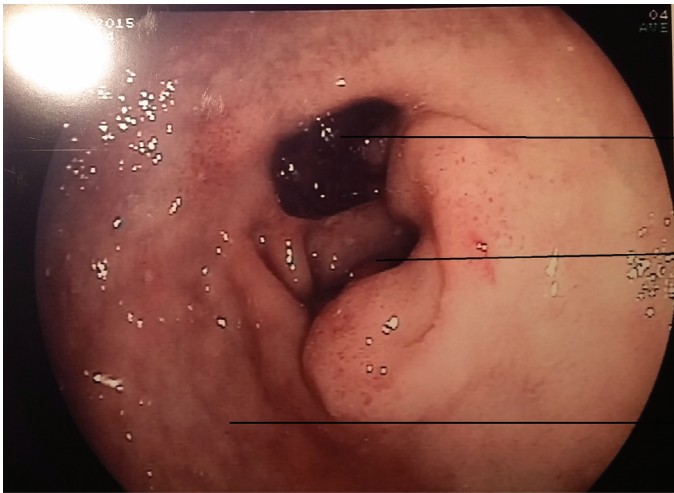


Dossier 23 – Question 6



Dossier 32 – Question 8





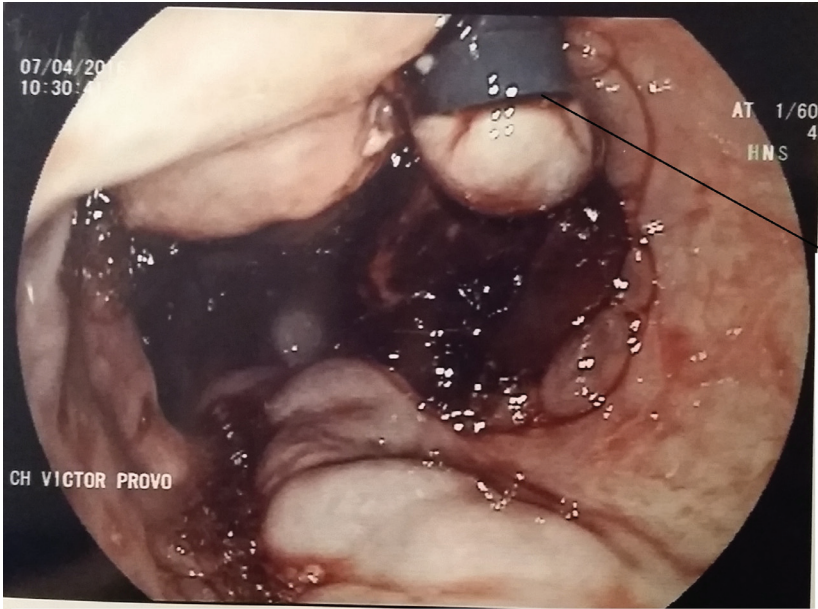
Caillot de sang

Lumière duodénale

Muqueuse duodénale normale

Pierre Mayer (décembre 2015)

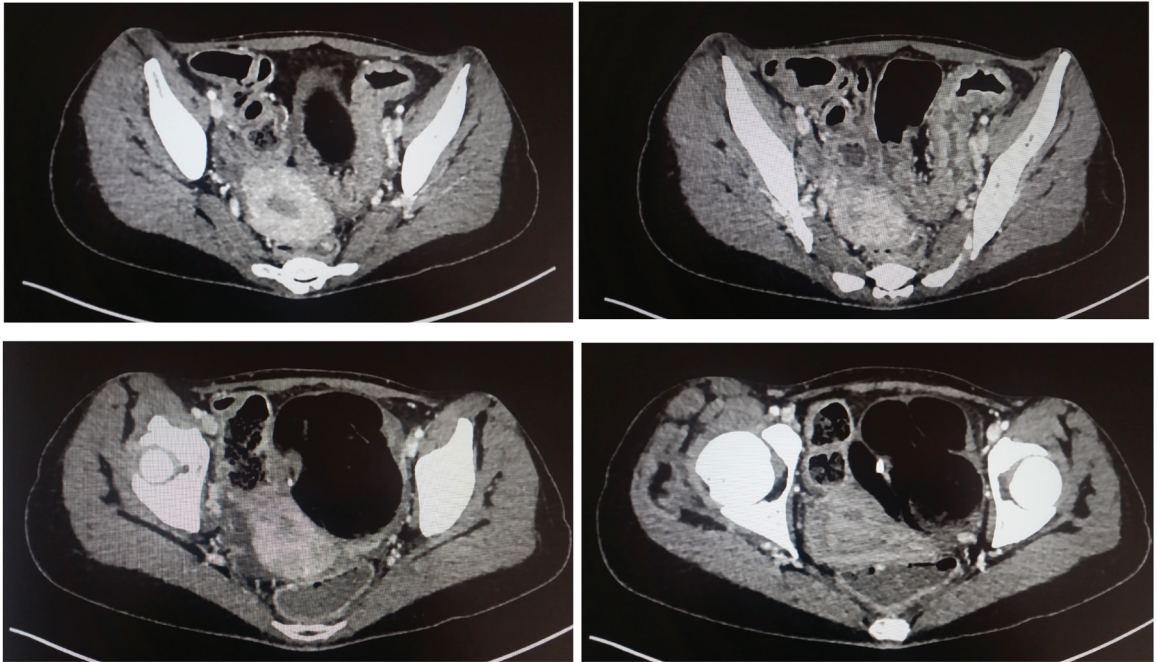
Dossier 26 – Question 6



Ligature de varice oesophagienne

Pierre Mayer (avril 2016)

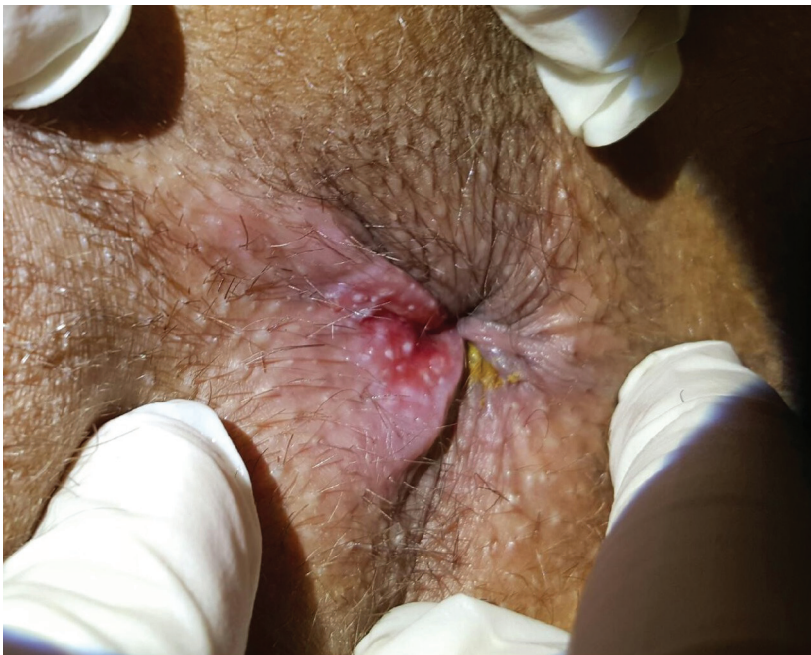Dossier 29 – Question 12



Scanner abdominopelvien avec  
injection de produit de contraste iodé

Pierre Mayer février 2015

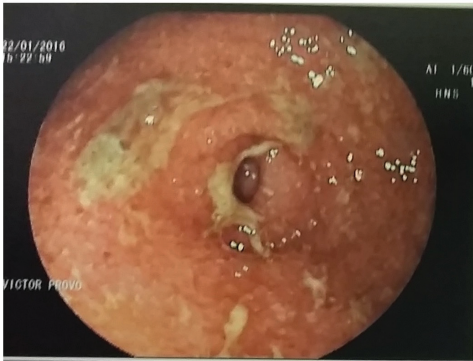
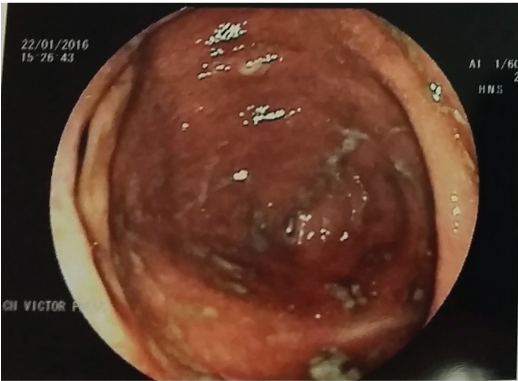
Dossier18 – Question 13



Pierre Mayer (janvier 2016)

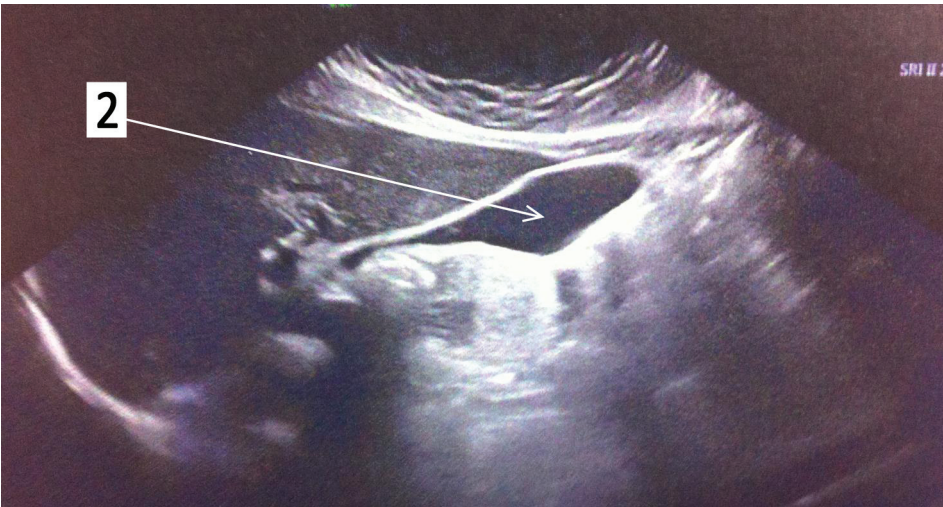Dossier 21 – Question 2



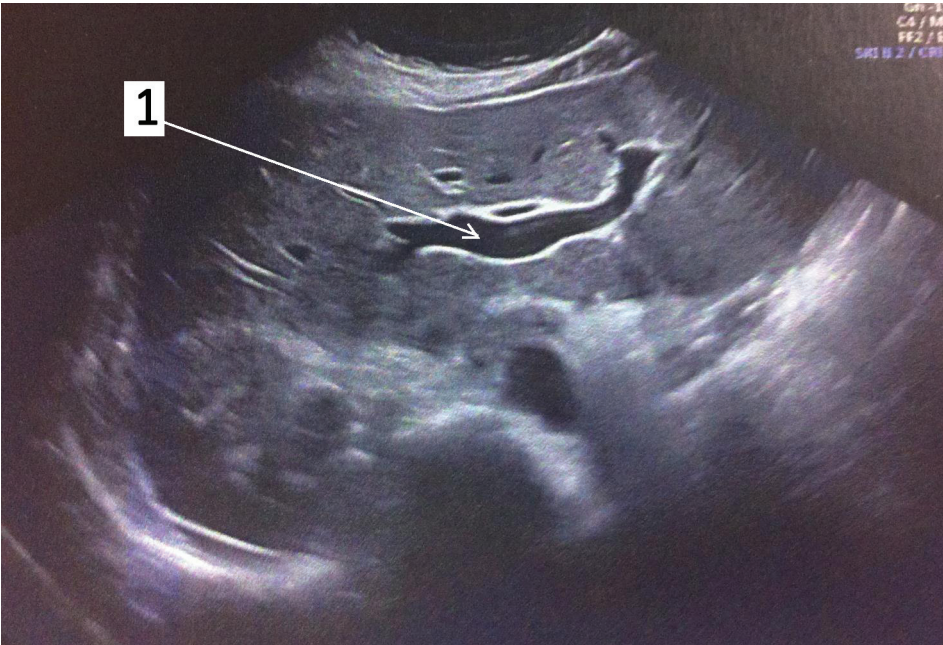


Pierre Mayer (janvier 2016)

Dossier18 – Question 8

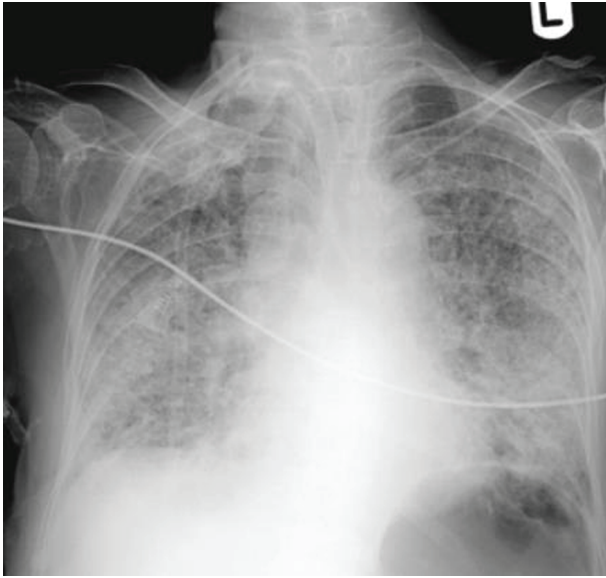


Dossier19 – Question 3

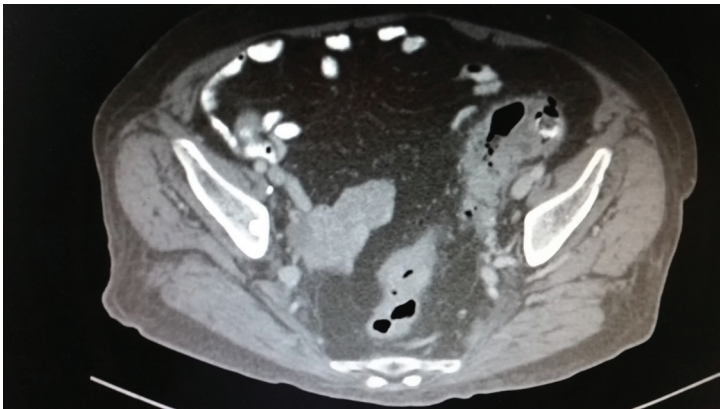


Dossier19 – Question 3

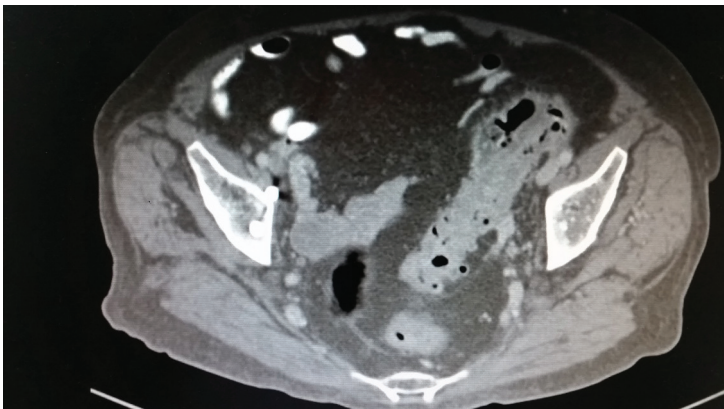




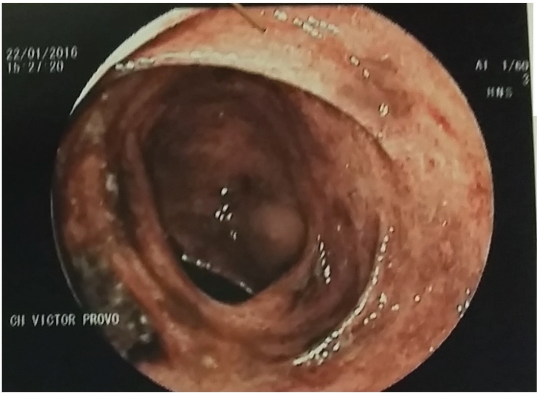
Dossier 23 – Question 7



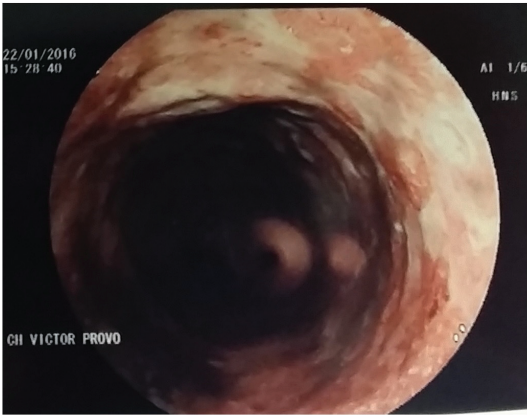
Dossier 14 – Question 10



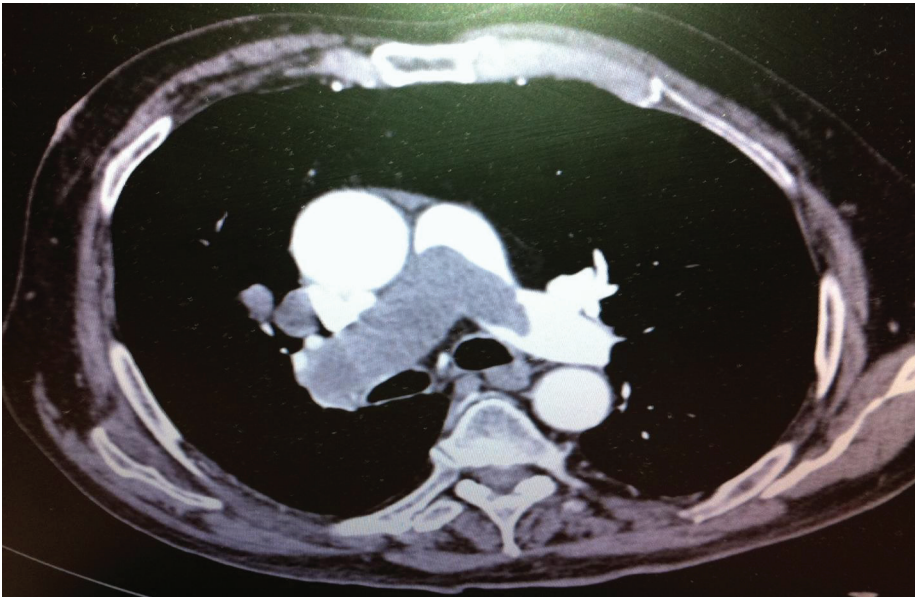
Dossier 14 – Question 10



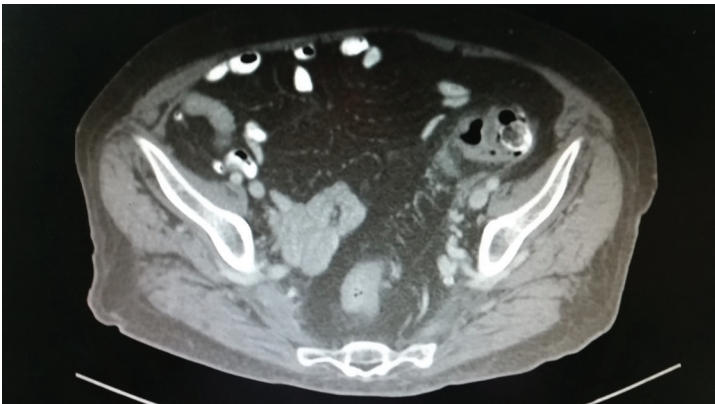
Pierre Mayer (janvier 2016)



Dossier18 – Question 8

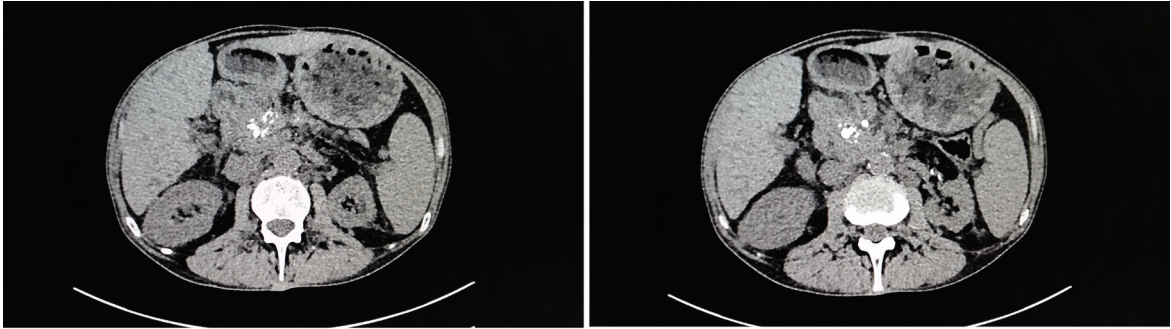


Dossier 33 – Question 13



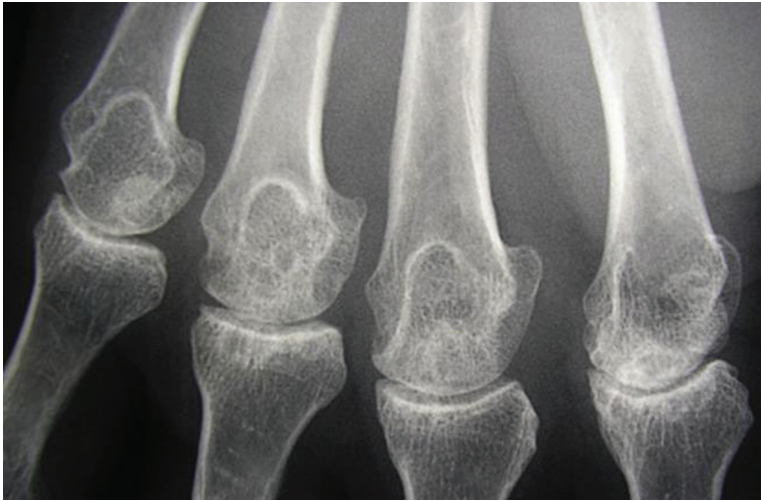Dossier 14 – Question 10



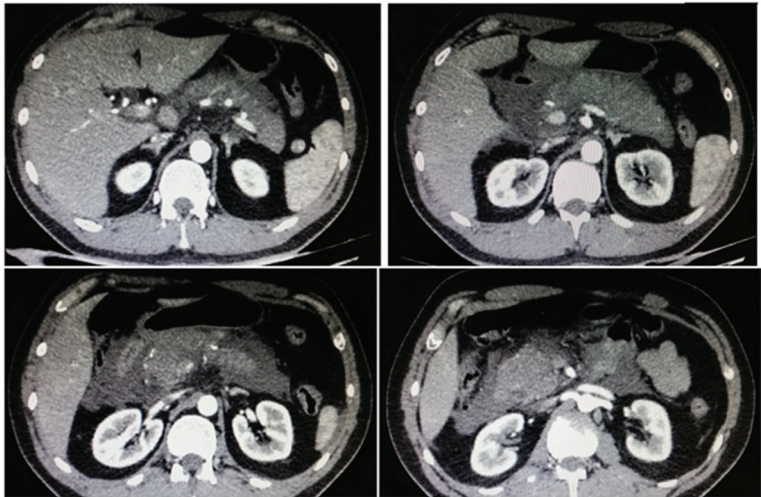


Scanner abdomino-pelvien sans injection de produit de contraste iodé  
Pierre Mayer (avril 2015))

Dossier 5 – Question 7

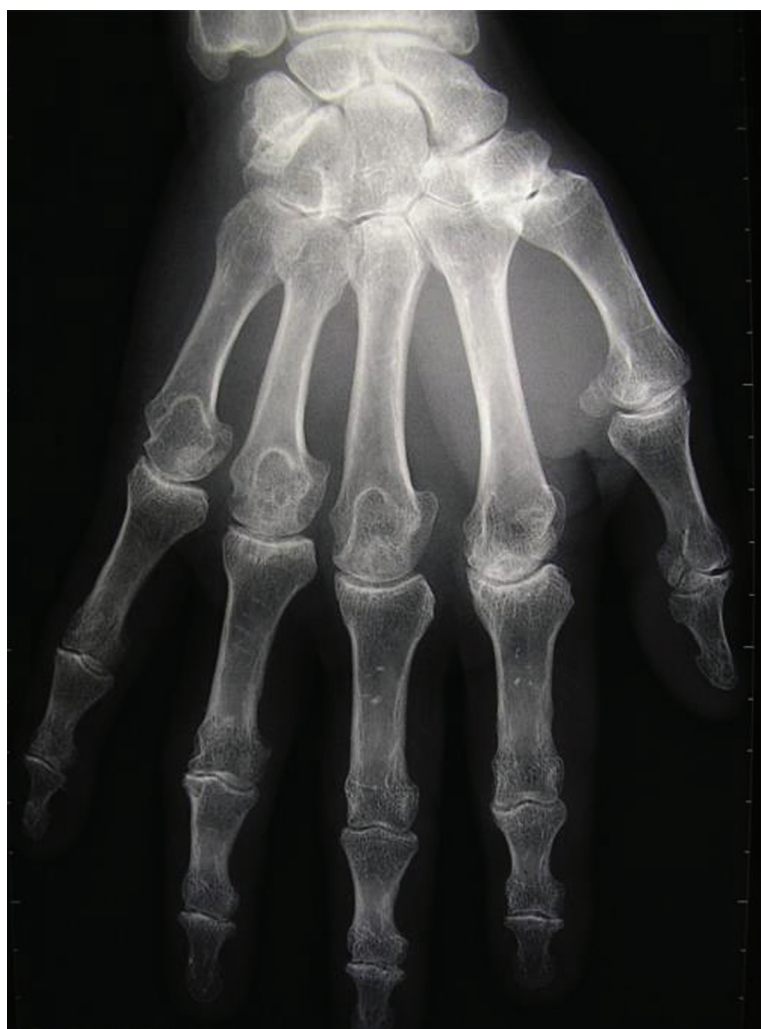

Dossier 32 - Énoncé



Dossier 5 – Question 5





Dossier 32 - Énoncé